



Ulnar Collateral Ligament Repair of the Elbow—Biomechanics, Indications, and Outcomes

Stephen J. Torres¹ · Orr Limpisvasti¹

Accepted: 8 January 2021 / Published online: 9 February 2021

© The Author(s), under exclusive licence to Springer Science+Business Media, LLC part of Springer Nature 2021

Abstract

Purpose of Review Traditionally medial elbow injuries in overhead athletes have been treated with ulnar collateral ligament (UCL) reconstruction as first described by Dr. Frank Jobe. Recent literature has shown favorable outcomes in select patients treated with UCL repair. Newer techniques utilizing suture augmentation demonstrate biomechanical profiles as good or better than the native state and/or reconstruction. This review aims to evaluate these biomechanical studies and the clinical outcomes of ulnar collateral ligament repair with suture augmentation.

Recent Findings UCL repair has favorable outcomes in select patients with specific tear type patterns. Clinical outcomes have shown return to play rates of 92–97% with mean time of 2.5–6 months post-operatively. Biomechanical data comparing UCL repair to reconstruction techniques have shown improved resistance to common forces applied to the elbow during overhead activities. Additionally, suture tape augmentation dramatically improves stability of ligament repair without over-constraining the elbow.

Summary Initial ulnar collateral ligament repair data was poor, and thus UCL reconstruction became the mainstay of treatment for overhead athletes. Recent studies evaluating the biomechanical properties as well as clinical outcomes have demonstrated favorable data when UCL repair is performed. When considering the drawbacks of a prolonged recovery associated with reconstruction, UCL repair is a viable option in select patients.

Keywords Ulnar collateral ligament repair · UCL · Internal brace · Suture augmentation

Introduction

The medial ulnar collateral ligament is the primary restraint to valgus stresses placed on the elbow [1]. Injury to this ligament can occur from traumatic events or through attritional changes commonly seen in overhead athletes leading to pain and discomfort [2]. With year-round athletics and single sport specialization, young athletes are seeing increased rates of injury to this ligament, and the question of how to best treat them is becoming more and more relevant [3, 4]. Initially, nonoperative management is often appropriate and may allow for some

athletes to return to the same level of activity [5, 6]. Others, however, may require surgical intervention to restore stability to the elbow.

Traditionally, ligament tears were destined for a reconstruction procedure as described by Dr. Frank Jobe in 1974 [7]. This technique has been modified since its original description and is widely accepted as an excellent operation with favorable outcomes. Despite its success, the procedure does have some drawbacks. The recovery time and return to play can be as long as 12–18 months for Major League Baseball (MLB) pitchers, and depending on when the surgery is performed could mean multiple seasons of lost time [8]. The prolonged recovery is necessary for graft maturation to occur which is avoided when direct ligament repair is performed. Furthermore, with these injuries occurring in younger athletes, the potential for higher quality tissue may obviate the need for tendon graft material.

Attempts at repair have been tried previously in traumatic cases in 1981 [9] as well as in high level overhead athletes in 1992 [10]; however, poor return to sports outcomes led to reconstruction being favored over repair in these patients. In 2006 however renewed interest in repair was seen in a series

This article is part of the Topical Collection on *Injuries in Overhead Athletes*

✉ Stephen J. Torres
stephenjtorres@gmail.com

Orr Limpisvasti
limpisvastimd@gmail.com

¹ Cedars-Sinai, Kerlan-Jobe Institute, 6801 Park Terrace, Los Angeles, CA 90045, USA

of favorable outcomes in female athlete as reported by Argo et al. [11]. This was followed up in 2008 with a series that looked at young nonprofessional athletes with proximal and distal injuries which found favorable outcomes with rapid return to sport. These two studies led to renewed interest in repair as an alternative to reconstruction in the right patient. With advancements made in orthopedic implants, newer repair techniques that incorporate suture augmentation have led to both improved biomechanical properties that are starting to show promise in clinical outcomes studies. Ultimately, the decision between repair and reconstruction should include a shared decision-making process with the surgeon and young athlete taking into consideration many factors related to not only the injury pattern but also career path and long-term goals.

Anatomy

The elbow joint is an inherently stable joint due to both static and dynamic restraints. The osseous articulation and complex capsuloligamentous structures contribute to the static stability of the elbow. The medial ulnar collateral ligament complex (MUCL) resist roughly a third of the valgus stress applied to the elbow at full extension and half of the valgus stress at 90° of flexion [1, 12]. Given this, the MUCL is considered the primary static stabilizer with the capsule and bony anatomy assuming secondary roles [13]. In addition to the static restraints, significant contributions to elbow stability are afforded to the dynamic muscular restraints of the flexor pronator mass (FPM). In cadaveric studies, the flexor carpi ulnaris (FCU) has been shown to be an important primary dynamic valgus stabilizer with the flexor digitorum superficialis (FDS) and pronator teres (PT) serving secondary roles [14, 15].

The MUCL is comprised of three structures—an anterior bundle, posterior bundle, and a transverse segment (Fig. 1). The anterior bundle of the ligament is easily distinguished

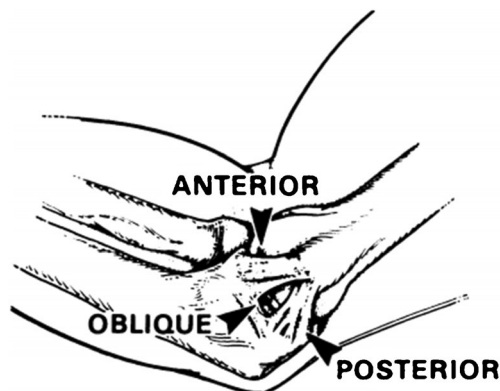


Fig. 1 Original depiction of the anatomy of medial ulnar collateral ligament of the elbow from Dr. Jobe in 1986. Reproduced with permission. <https://doi.org/10.2106/00004623-198668080-00004>

from the capsule and originates proximally at the inferior most aspect of medial epicondyle of the humerus and inserts distally at the sublime tubercle [16]. It has an overall length of 4.7–5.4 cm and width of 4.7 mm. The insertion of the ligament is spread out over a large footprint that extends distally from the sublime tubercle along the ulnar ridge and accounts for more than half of the total length of the ligament [17]. The anterior bundle can be further divided into an anterior band that is taut from 30 to 90° flexion and a posterior band that is taut at 90–120° of flexion [18]. Posteriorly, the ligament is seen as a fan-shaped thickening of the capsule that is only clearly distinguishable at 90° of flexion with a mean width of 5.3 mm. The posterior portion originates at the posterior aspect of the medial epicondyle and inserts onto the semilunar notch of the ulna and has a mean length of 24.2 mm. The transverse portion of the ligament consist of horizontally oriented fibers of the medial capsule extending from the medial olecranon to the inferomedial coronoid process. This portion of the ligament is often indistinguishable from the medial capsule and confers limited stability to the elbow [1, 12].

Biomechanics

The native MUCL has been shown to have a mean ultimate load to failure of approximately 32–34 Nm [19, 20]. Considering that the valgus stress on the elbow has been measured to be between 64 and 120 Nm during the early acceleration phase of throwing, there theoretically is enough force to tear the ligament with every throw [21, 22]. Adaptive changes to the ligament itself, bone-to-bone interference at higher flexion angles, as well as dynamic muscle contractions of the forearm muscles serve to protect the elbow from this occurring [23].

Biomechanical analysis has shown the significant role the anterior band play in resisting valgus load. Sectioning the ligament and applying a valgus torque increased rotation from 3.6° in an intact state to 6.8° at 90° of flexion in the sectioned state—an 88% increase [18]. Further analysis of the ligament has shown that through the elbow range of motion, the anterior band of the anterior bundle has an isometric strain pattern, while the posterior band has an increasing strain pattern with higher degrees of flexion which has important clinical implications during both surgical repair and reconstruction [23, 24].

Reconstruction of the ligament has been shown to restore ultimate load to failure data to near intact states with several different modification of the original Jobe technique and fixation methods at various range of motions. Additionally, gap formation and rotational torque resistance have been shown to be similar to intact states [19, 23, 25, 26, 27]. With the renewed interest in repair and utilization of suture augmentation, several biomechanical studies have sought to compare the technique to the gold standard reconstruction techniques.

In 2016, Dugas et al. [28] compared their repair technique with suture augmentation to the modified Jobe technique. The authors placed their suture augment with a single anchor at the apex of the sublime tubercle and the center point of the native UCL footprint at the anterior inferior medial epicondyle. They found that the repair group showed greater resistance to gapping compared to the reconstruction group. No difference was seen between the groups with regard to torsional stiffness and ultimate torque at failure. Dugas et al. [29] followed this up in 2018 utilizing a cyclic fatigue model of 500 cycles to show that UCL repair with suture augmentation is more resistant to gapping under fatigue loading compared to reconstruction techniques suggesting potential changes to the tendon graft as it undergoes cyclic loading over time.

In 2018, Bodendorfer et al. [30] sought to compare their repair technique to the modified docking technique as the previous studies looked at the modified Jobe technique. Their repair technique also placed the suture augment at the center of the anterior bundle. They concluded that both repair and reconstruction provided valgus stability comparable to the native ligament and no statistical difference between load to failure, gapping, and valgus opening angle was seen between the techniques. The study only evaluated the constructs at 90°.

In 2019, Urch et al. [27] evaluated their repair technique and compared this to the modified docking reconstruction technique. Their repair technique placed the suture augment along the posterior band of the anterior bundle as opposed to the center of the anterior bundle as seen in the previous studies (Fig. 2). The authors found that valgus laxity was restored to the intact state at full extension and 30°.

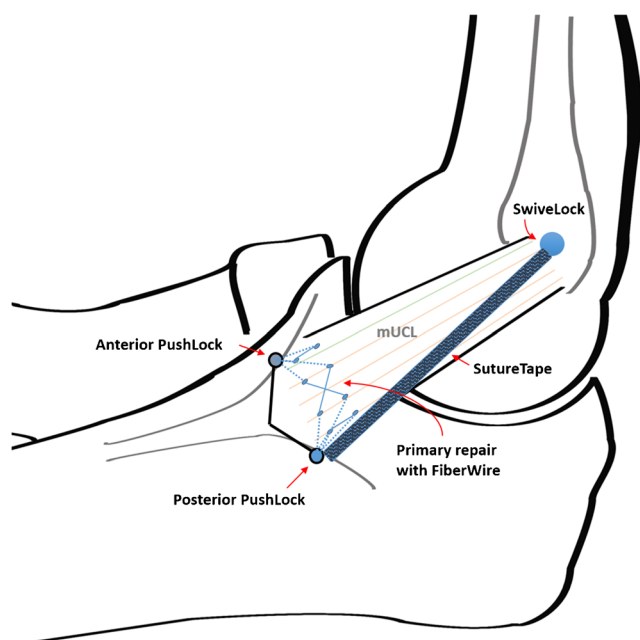


Fig. 2 Schema of modified repair-IB construct showing suture tape augmentation along posterior band of the anterior bundle. Reproduced with permission. <https://doi.org/10.1177/2325967119874135>

Interestingly, valgus laxity was not restored in the reconstruction group at full extension or 30° and over constrained at the higher flexion angles. When loaded to failure, however the reconstruction group showed greater yield torque and ultimate torque. The investigators concluded that augmenting the posterior band of the anterior bundle provided the best resistance to valgus load due to the increase loads seen at high flexion angles.

In 2020, Bachmaier et al. [20] also compared repair with suture augmentation and the modified docking technique however sought to also evaluate repair alone. Like previous studies, the authors found that repair with suture augmentation showed significantly higher torsional stiffness and residual torque compared to the other groups. Repair alone, however, was only marginally better than the torn state. Reconstruction showed similar initial stiffness and residual torque to the intact state; however, at higher valgus rotations, the stiffness decreased to levels of the repair alone and torn states. This is similar to previous studies, and the authors concluded that this may be the result of the graft stretching or fixation slippage.

These biomechanical studies provide support for the consideration of repair over reconstruction as their biomechanical properties in most cases are similar and, in some instances, better than that seen in reconstruction techniques.

Indications for UCL Repair [31]

Initial management of injuries to the MUCL typically involves a period of nonoperative treatment with relative rest and avoidance of throwing. Depending on the severity of the injury, return to play rates can be as high as 93–100% for grade I partial tears [6, 32]. Higher grade injuries can have some success with nonoperative treatment however ultimately may require surgical intervention to allow the athlete to return to sport.

Many factors need to be considered when dealing with medial elbow injuries, and a clear discussion with the patient and their family regarding their overall treatment goals is necessary. Considerations for tear location, grade of injury, chronicity, quality of tissue, appearance on MRI, patient age, position, in-seasons vs off-season, desire to return to play, and competitive vs noncompetitive athlete are all factors that should be considered and discussed when devising a treatment plan. Patients with proximal or distal tears with good quality tissue are potentially good candidates for direct repair [31]. Mid-substance tears with poor quality tissue on MRI or presence of ossicles within the ligament on the other hand are likely poor candidates. In some instances, intraoperative evaluation of tissue quality may be necessary, and surgical consent should include both repair and reconstruction in these patients.

Outcomes of UCL Repair

In 1981, Norwood et al. [9] published their series of primary repair of the medial collateral ligament in 4 recreational athletes with acute disruption. All patients were able to return to their previous activity levels in 2 years. This paved the way for direct repair being a treatment option. In 1992, however, Conway et al. [10] published their series of patients in throwing athletes who underwent repair or reconstruction. In the repair group, only 50% of their patients were able to return to the professional level. In a subanalysis of those, only 29% were able to return to their same level of play or higher which contrasted with their reconstruction group that showed 75% were able to return to the same level of play or higher. Similar

results were seen by Azar et al. in 2000 which showed 63% return to play in the repair group compared to 81% in their reconstruction group [33].

In 2006, Argo et al. [11] published their series of overhead female athletes which was the first reports of promising results of repair with 17 of 18 athletes able to return to the same level of play. Furthermore, they showed that the mean time to return was 2.5 months post-operatively which is in stark contrast to the typical times seen with reconstruction. In a follow-up study, in 2008, Savoie et al. [31] included both male and female athletes and showed 93% good to excellent outcomes and 97% return to same level of play or higher. The repair technique in these cases was suture repair with either bone drill holes or suture anchors in patients with either proximal

Table 1 Outcomes of ulnar collateral ligament repair in published studies

Year	Author	# of repairs	Surgical technique	Suture augment	Gender	Mean age	Primary sport	Level of competition	Outcomes
2019	Dugas et al. [35••]	111	Repair suture and suture tape augment secured with anchors	Yes—collagen dippe-d	Male Female	18.3	Baseball Football softball Javelin	High school (67%), college (28%), recreational (4%), professional (1%), junior high (1%)	102/111 (92%)—returned to previous/higher level of play Average time to return: 6.7 months
2008	Savoie et al. [31]	60	Suture/anchor bone tunnels	No	Male Female	17.2	Baseball Basketball Cheerleading	College (37%), high school (42%), junior high (21%)	56/60 (93%)—returned to previous/higher level of play Average time to return: 6 months (4–11.7 months)
2006	Argo et al. [11]	18	10—repair/suture anchor 6—repair/plication 1—repair/muscle augmentation 1—bone tunnel	No	Female	22	Softball Gymnastics Tennis	College (47%), high school (26%), recreational (21%), nonathlete (5%)	17/18 (94%)—returned to previous/higher level of play Average time to return: 2.5 months (2–3.5 months)
2000	Azar et al. [33]	13	Did not specify	No	Male	21.6	Baseball Football Tennis Wrestling	Professional, collegiate, high school (percentages not specified)	5/8 (63%)—returned to previous/higher level of play (5 lost to follow-up)
1992	Conway et al. [10]	14	10—repair/plication 4—bone tunnels	No	Male	26.5	Baseball	Professional (71%), collegiate (29%)	7/14 (50%)—returned to previous level of play
1981	Norwood et al. [9]	4	3—repair/plication 1—bone tunnel	No	Male		Softball Soccer	Recreational (50%), nonathlete (50%)	4/4 (100%)—returned to previous level of play 2/4—nondominant arm 1/4—returned to throwing 1/4—returned to soccer

or distal injuries. Professional athletes were not included in this study which the authors concluded likely contributed to their high level of success as overall the tissue quality in their patients was quite good. Additionally, the mean age of their patients was 17.2 years. These results however highlight the importance of proper patient selection for good outcomes.

In recent years, the development of high-tensile strength suture tape material has led to reports of repair with suture augmentation. In 2018, Dugas et al. [34] presented their abstract of prospective data in 56 overhead athletes undergoing repair with augmentation and showed 96% return to play at a mean of 6.1 months. In 2019, Dugas et al. [35••] published on 111 overhead athletes who underwent repair with a novel collagen-dipped suture tape and showed 92% return to the same level of play or higher at a mean time of 6.7 months post-operatively.

These studies demonstrate that in select patients, repair can produce excellent outcomes with the potential for faster return to play over reconstruction (Table 1).

Conclusion

UCL repair has excellent outcomes with favorable return to play data when utilized in the right patient. Considerations for tear type and location as well as specific athlete circumstances will contribute to the success of the procedure. Careful selection criteria should be considered when determining between UCL repair and reconstruction in treating athletes with medial elbow injuries.

Compliance with Ethical Standards

Conflict of Interest Stephen Torres and Orr Limpisvasti declare they have no conflict of interest.

Human and Animal Rights and Informed Consent This article does not contain any studies with human or animal subjects performed by any of the authors.

References

Papers of particular interest, published recently, have been highlighted as:

- Of importance
- Of major importance

1. Morrey BF, An KN. Articular and ligamentous contributions to the stability of the elbow joint. *Am J Sports Med.* 1983;11:315–9. <https://doi.org/10.1177/036354658301100506>.
2. Richard MJ, Aldridge JM, Wiesler ER, Ruch DS. Traumatic valgus instability of the elbow: pathoanatomy and results of direct repair. *Surgical technique J Bone Joint Surg Am.* 2009;91:191–9. <https://doi.org/10.2106/JBJS.I.00426>.
3. Erickson BJ, Nwachukwu BU, Rosas S, Schairer WW, McCormick FM, Bach BR, et al. Trends in medial ulnar collateral ligament reconstruction in the United States: a retrospective review of a large private-payer database from 2007 to 2011. *Am J Sports Med.* 2015;43:1770–4. <https://doi.org/10.1177/0363546515580304>.
4. Olsen SJ, Fleisig GS, Dun S, Loftice J, Andrews JR. Risk factors for shoulder and elbow injuries in adolescent baseball pitchers. *Am J Sports Med.* 2006;34:905–12. <https://doi.org/10.1177/0363546505284188>.
5. Rettig AC, Sherrill C, Snead DS, Mendler JC, Mielsing P. Nonoperative treatment of ulnar collateral ligament injuries in throwing athletes. *Am J Sports Med.* 2001;29:15–7. <https://doi.org/10.1177/03635465010290010601>.
6. Smucny M, Westermann RW, Winters M, Schickendantz MS. Non-operative management of ulnar collateral ligament injuries in the throwing athlete. *Phys Sportsmed.* 2017;45:234–8. <https://doi.org/10.1080/00913847.2017.1358585>.
7. Jobe FW, Stark H, Lombardo SJ. Reconstruction of the ulnar collateral ligament in athletes. *J Bone Jt Surg - Ser A.* 1986;68:1158–63. <https://doi.org/10.2106/00004623-198668080-00004>.
8. Makhni EC, Lee RW, Morrow ZS, Gualtieri AP, Gorroochurn P, Ahmad CS. Performance, return to competition, and reinjury after Tommy John surgery in major league baseball pitchers: a review of 147 cases. *Am J Sports Med.* 2014;42:1323–32. <https://doi.org/10.1177/0363546514528864>.
9. Norwood LA, Shook JA, Andrews JR. Acute medial elbow ruptures. *Am J Sports Med.* 1981;9:16–9. <https://doi.org/10.1177/036354658100900103>.
10. Conway JE, Jobe FW, Glousman RE, Pink M. Medial instability of the elbow in throwing athletes. Treatment by repair or reconstruction of the ulnar collateral ligament. *J Bone Jt Surg - Ser A.* 1992;74:67–83. <https://doi.org/10.2106/00004623-199274010-00009>.
11. Argo D, Trenhaile SW, Savoie FH, Field LD. Operative treatment of ulnar collateral ligament insufficiency of the elbow in female athletes. *Am J Sports Med.* 2006;34:431–7. <https://doi.org/10.1177/0363546505281240>.
12. Morrey BF, An KN. Functional anatomy of the ligaments of the elbow. *Clin Orthop Relat Res NO.* 1985;201:84–90.
13. Morrey BF, Tanaka S, An KN. Valgus stability of the elbow. A definition of primary and secondary constraints. *Clin Orthop Relat Res.* 1991;187–95. <https://doi.org/10.1097/00003086-199104000-00021>.
14. Park MC, Ahmad CS. Dynamic contributions of the flexor-pronator mass to elbow valgus stability. *J Bone Jt Surg - Ser A.* 2004;86:2268–74. <https://doi.org/10.2106/00004623-200410000-00020>.
15. Lin F, Kohli N, Perlmutter S, Lim D, Nuber GW, Makhosous M. Muscle contribution to elbow joint valgus stability. *J Shoulder Elb Surg.* 2007;16:795–802. <https://doi.org/10.1016/j.jse.2007.03.024>.
16. O'Driscoll SW, Jalszynski R, Morrey BF, An KN. Origin of the medial ulnar collateral ligament. *J Hand Surg Am.* 1992;17:164–8. [https://doi.org/10.1016/0363-5023\(92\)90135-C](https://doi.org/10.1016/0363-5023(92)90135-C).
17. Farrow LD, Mahoney AJ, Stefancin JJ, Taljanovic MS, Sheppard JE, Schickendantz MS. Quantitative analysis of the medial ulnar collateral ligament ulnar footprint and its relationship to the ulnar sublime tubercle. *Am J Sports Med.* 2011;39:1936–41. <https://doi.org/10.1177/0363546511406220>.
18. Callaway GH, Field LD, Deng XH, Torzilli PA, O'Brien SJ, Altchek DW, et al. Biomechanical evaluation of the medial collateral ligament of the elbow. *J Bone Jt Surg - Ser A.* 1997;79:1223–31. <https://doi.org/10.2106/00004623-199708000-00015>.
19. Ahmad CS, Lee TQ, ElAttrache NS. Biomechanical evaluation of a new ulnar collateral ligament reconstruction technique with interference screw fixation. *Am J Sports Med.* 2003;31:332–7. <https://doi.org/10.1177/03635465030310030201>.

20. Bachmaier S, Wijdicks CA, Verma NN, Higgins LD, Greiner S. Biomechanical functional elbow restoration of acute ulnar collateral ligament tears: the role of internal bracing on gap formation and repair stabilization. *Am J Sports Med.* 2020;48:1884–92. <https://doi.org/10.1177/0363546520921174>.
21. Werner SL, Fleisig GS, Dillman CJ, Andrews JR. Biomechanics of the elbow during baseball pitching. *J Orthop Sports Phys Ther.* 1993;17:274–8. <https://doi.org/10.2519/jospt.1993.17.6.274>.
22. Fleisig GS, Andrews JR, Dillman CJ, Escamilla RF. Kinetics of baseball pitching with implications about injury mechanisms. *Am J Sports Med.* 1995;23:233–9. <https://doi.org/10.1177/036354659502300218>.
23. Ciccotti MG, Siegler S, Kuri JA, Thinnes JH, Murphy DJ IV. Comparison of the biomechanical profile of the intact ulnar collateral ligament with the modified Jobe and the docking reconstructed elbow: An in vitro study. *Am J Sports Med.* 2009;37:974–81. <https://doi.org/10.1177/0363546508331136>.
24. Jackson TJ, Jarrell SE, Adamson GJ, Chung KC, Lee TQ. Biomechanical differences of the anterior and posterior bands of the ulnar collateral ligament of the elbow. *Knee Surgery, Sport Traumatol Arthrosc.* 2016;24:2319–23. <https://doi.org/10.1007/s00167-014-3482-7>.
25. Mullen DJ, Goradia VK, Parks BG, Matthews LS. A biomechanical study of stability of the elbow to valgus stress before and after reconstruction of the medial collateral ligament. *J Shoulder Elb Surg.* 2002;11:259–64. <https://doi.org/10.1067/mse.2002.122622>.
26. McAdams TR, Lee AT, Centeno J, Giori NJ, Lindsey DP. Two ulnar collateral ligament reconstruction methods: the docking technique versus bioabsorbable interference screw fixation—a biomechanical evaluation with cyclic loading. *J Shoulder Elb Surg.* 2007;16:224–8. <https://doi.org/10.1016/j.jse.2005.12.012>.
27. Urch E, Limpisvasti O, ElAttrache NS, Itami Y, McGarry MH, Photopoulos CD, et al. Biomechanical evaluation of a modified internal brace construct for the treatment of ulnar collateral ligament injuries. *Orthop J sport med.* 2019. <https://doi.org/10.1177/2325967119874135> **provides evidence of benefits of placing suture augment inline with posterior band of anterior bundle.**
28. Dugas JR, Walters BL, Beason DP, Fleisig GS, Chronister JE. Biomechanical comparison of ulnar collateral ligament repair with internal bracing versus modified Jobe reconstruction. *Am J Sports Med.* 2016;44:735–41. <https://doi.org/10.1177/0363546515620390>.
29. Jones CM, Beason DP, Dugas JR. Ulnar collateral ligament reconstruction versus repair with internal bracing: comparison of cyclic fatigue mechanics. *Orthop J Sport Med.* 2018;6:232596711875599. <https://doi.org/10.1177/2325967118755991>.
30. Bodendorfer BM, Looney AM, Lipkin SL, Nolton EC, Li J, Najarian RG, et al. Biomechanical comparison of ulnar collateral ligament reconstruction with the docking technique versus repair with internal bracing. *Am J sports med.* 2018. <https://doi.org/10.1177/0363546518803771> **compares repair alone with intact, repair with augmentation and docking reconstruction techniques.**
31. Savoie FH, Trenhaile SW, Roberts J, Field LD, Ramsey JR. Primary repair of ulnar collateral ligament injuries of the elbow in young athletes: a case series of injuries to the proximal and distal ends of the ligament. *Am J Sports Med.* 2008;36:1066–72. <https://doi.org/10.1177/0363546508315201>.
32. Ford GM, Genuario J, Kinkartz J, Githens T, Noonan T. Return-to-play outcomes in professional baseball players after medial ulnar collateral ligament injuries comparison of operative versus nonoperative treatment based on magnetic resonance imaging findings. *Am J Sports Med.* 2016;44:723–8. <https://doi.org/10.1177/0363546515621756>.
33. Azar FM, Andrews JR, Wilk KE, Groh D. Operative treatment of ulnar collateral ligament injuries of the elbow in athletes. *Am J Sports Med.* 2000;28:16–23. <https://doi.org/10.1177/03635465000280011401>.
34. Dugas JR, Looze CA, Jones CM, Walters BL, Rothermich MA, Emblom BA, et al. Ulnar collateral ligament repair with internal brace augmentation in amateur overhead throwing athletes. *Orthop J Sport Med.* 2018;6:2325967118S0008. <https://doi.org/10.1177/2325967118s00084>.
35. Dugas JR, Looze CA, Capogna B, et al. Ulnar collateral ligament repair with collagen-dipped FiberTape augmentation in overhead-throwing athletes. *Am J Sports Med.* 2019. <https://doi.org/10.1177/0363546519833684> **Provides clinical outcomes on a large number of patients demonstrating high levels of return to play.**

Publisher's note Springer Nature remains neutral with regard to jurisdictional claims in published maps and institutional affiliations.